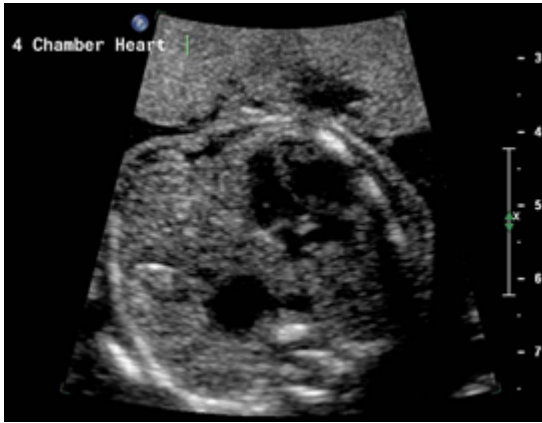
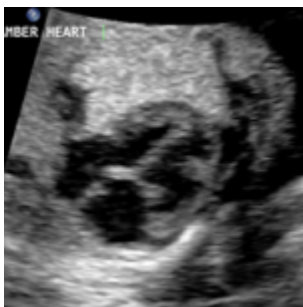
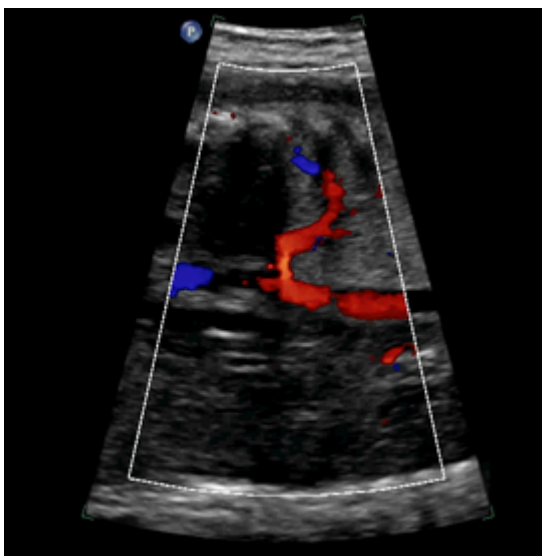
Abnormal Fetal Chest Ultrasound Images



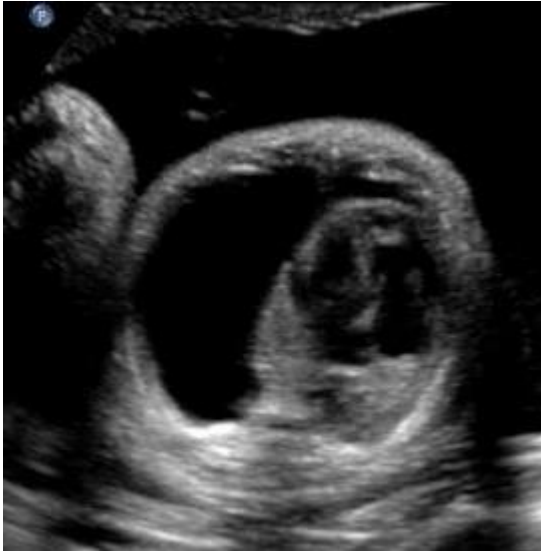Above. Congenital Diaphragmatic Hernia (CDH)



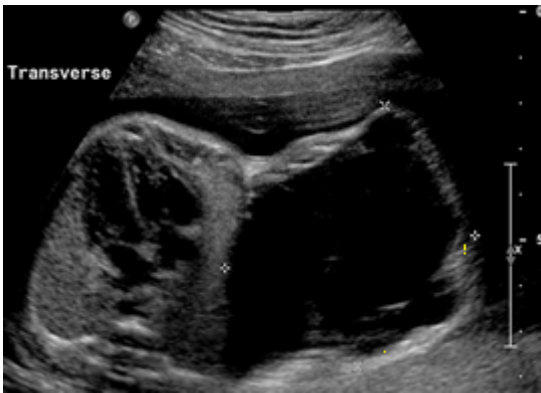Above. Congenital Pulmonary Airway Malformation (CPAM)



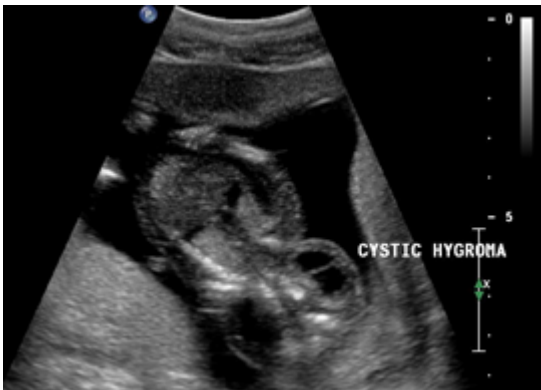Above. Bronchopulmonary Sequestration (BPS)



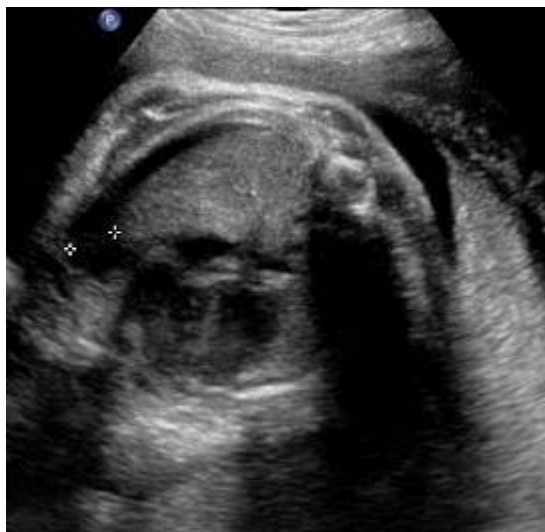Above. Pleural Effusion



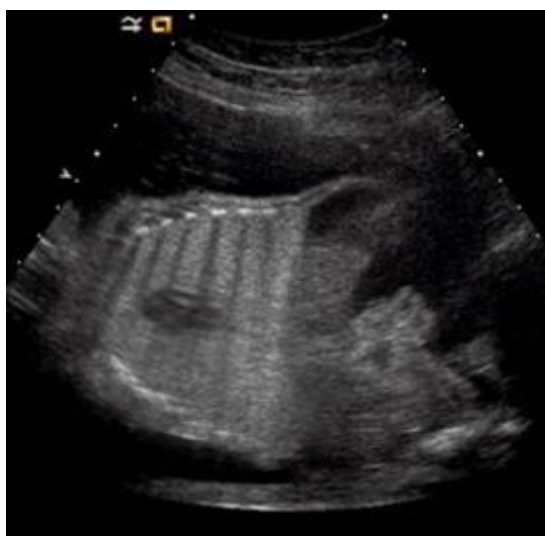Above. Lymphangioma



Above. Cystic Hygroma



Above. Chylothorax



Above. Congenital High Airway Obstruction Syndrome (CHAOS)

