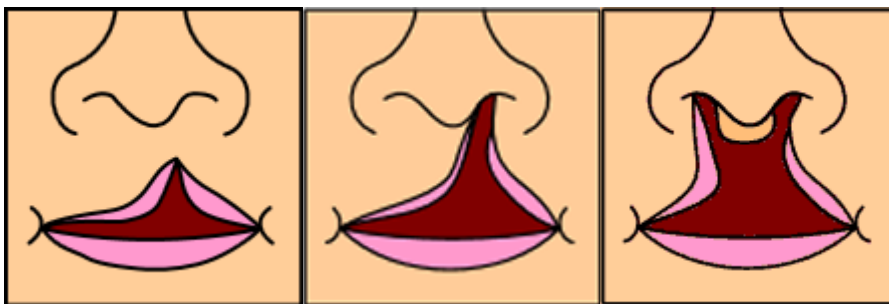


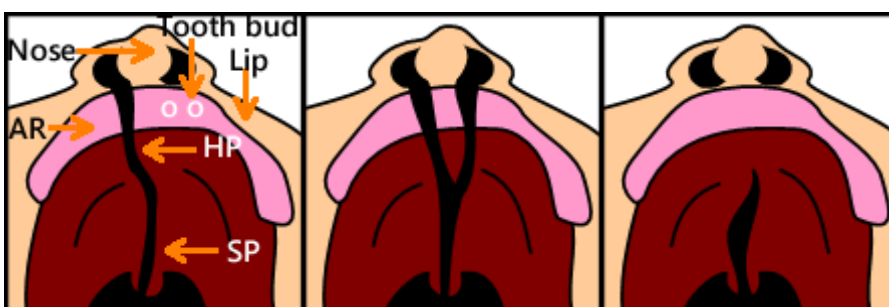
# Facial Clefts

**Page Links:** [Introduction](#), [Incidence](#), [Distribution of Facial Clefts](#), [Accuracy Prenatal Diagnosis](#), [Low-Risk Population](#), [High-Risk Population](#), [Ultrasound Scanning Technique](#), [3-D Ultrasound](#), [MRI](#), [Facial Clefts: Summary](#), [References](#)

## Introduction



Above. Types of orofacial clefts (cleft lip). Left: Unilateral incomplete cleft lip. Middle: Unilateral complete cleft lip. Right: Bilateral complete cleft lip. (Graphics: Originally from Wikipedia; in Public Domain).

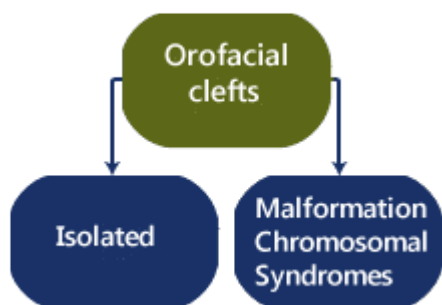


Above. Types of orofacial cleft palate. Left: Unilateral complete cleft lip and palate. Middle: Bilateral complete cleft lip and palate. Right: Unilateral incomplete cleft palate. (Graphics: Originally from Wikipedia; in Public Domain).

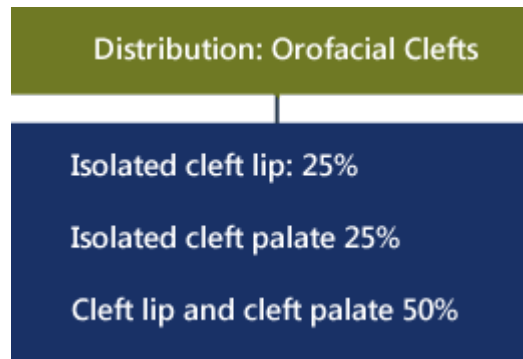
AR = alveolar ridge; HP=hard palate; SP=soft palate.

Facial clefts are classified as cleft lip (CL), cleft lip and cleft palate (CLP), and cleft

palate (CP). Environmental and genetic factors may be responsible when errors in the developmental process occur, and these include failure to “fuse, merge, or interact.” [\[1\]](#)



Above. Facial clefts may be isolated or they may be associated with malformations, karyotype abnormalities, and syndromes.



Above. Over 300 syndromes have been described with facial clefts, and the distribution according to the type of cleft is [\[2\]](#): isolated cleft lip 25%, isolated cleft palate 25%, and cleft lip and cleft palate 50%. This distribution has remained relatively constant over 4 decades.

## Incidence

### Incidence: Orofacial Clefts

1.82 and 1.3 per 1000 live births

Approximately 1 in 500 to 1 in 1000 live births

The incidence of cleft lip and palate is reported as 1.82 per 1000 live births [\[3\]](#) and 1.3 per 1000 live births [\[4\]](#) or approximately 1 in 500 to 1 in 1000 live births.

## Distribution of Facial Clefts

### Associations: Orofacial Clefts

57%: Isolated

43%: Not isolated

10% Chromosomal

12% Syndromes or sequences

21% Malformations

Above. In one study of 101 facial clefts among 49,314 deliveries, 57% of the facial clefts were isolated and among the 43% remaining clefts: 10% were associated with chromosomal aberrations, 12% with syndromes or sequences, and 21% with structural malformations only. [\[5\]](#)

Associated malformations are more common in cleft lip with palate than with cleft lip alone (34% versus 20%), and there is a 1.7 male to female predominance among those with cleft lip and palate. [\[6\]](#)

## Malformations: Orofacial Clefts

### Cleft lip/cleft palate:

Associated malformations: 29%  
1 or more malformations: 27%  
Most common: heart, lung, CNS

In a study of 6 million births, associated malformations were noted in 29.2% of CLP patients. About 27% of CLP patients will demonstrate one or more malformations. [7] Among infants with CL or CLP; heart, limb, and central nervous system are the most common anomalies. [8] Among those with cleft lip with cleft palate, the left side of the face tends to be predominant.

## Accuracy of Prenatal Diagnosis

### Low-Risk Population

#### Accuracy: Prenatal diagnosis: 2D-US

#### Systematic review detection rate:

Any type cleft: 9% to 73%  
Cleft lip with/without palate: 9 to 100%  
Cleft palate: 7%

In a systematic review of 421 studies, the accuracy varied widely with 2-D ultrasound for the prenatal diagnosis of cleft lip with or without cleft palate. Among low-risk populations, the diagnostic accuracy varied from 9% to 73% to detect any type of cleft. To detect cleft lip with or without cleft palate, the diagnostic accuracy varied from 9% to 100%; and to detect cleft palate alone, the diagnostic accuracy was 7%. [9] Cleft palate without the presence of cleft lip was rarely detected in the primary care setting unless there were a combined 2-D and 3-D ultrasound approach.

## High-Risk Population

Accuracy: Prenatal diagnosis: 3D-US

Systematic review detection rate:

Cleft lip with/without palate:  
60% to 100%

In that same review, improved rates of detection (60% to 100%) for cleft lip with or without cleft palate occurred when 3-D ultrasound was used in a tertiary care setting.

## Ultrasound Scanning Technique

US Scanning Technique: 2D US

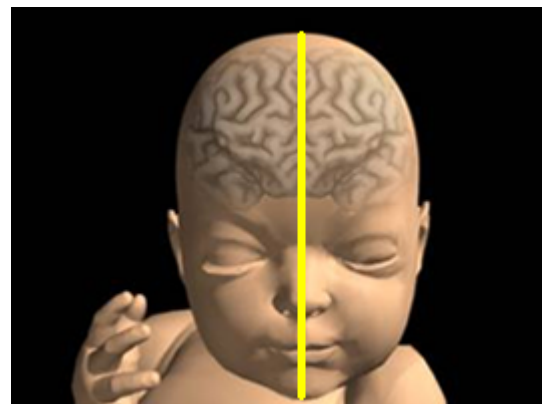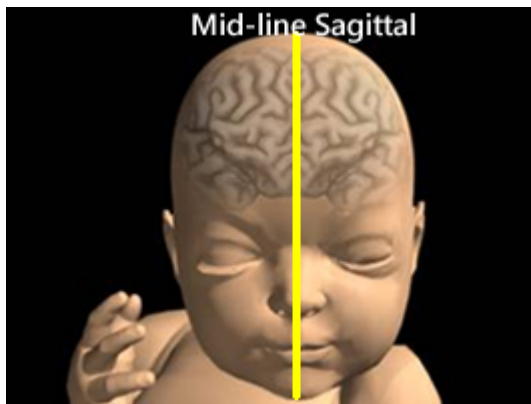1. Obtain image in anterior coronal plane

Move probe from nose and mouth to edge of lips

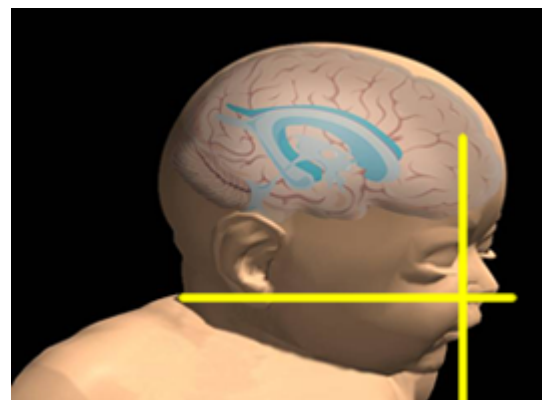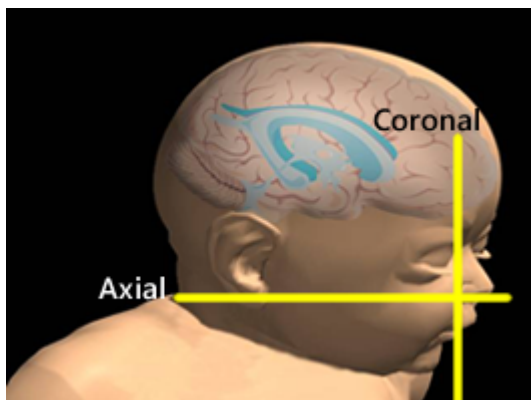
Obtain classic nose-mouth view

2. Attempt serial axial/transverse views and assess upper alveolar ridge, palate, tongue and mandible

3. At or < 20 weeks, attempt transvaginal ultrasound

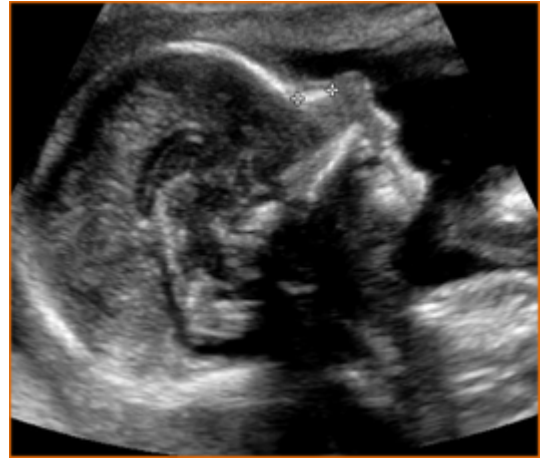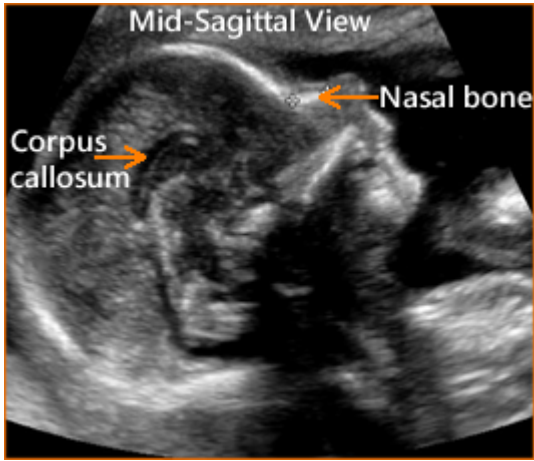


Above. Planes of view for cleft lip, and cleft palate. Mid-line sagittal.

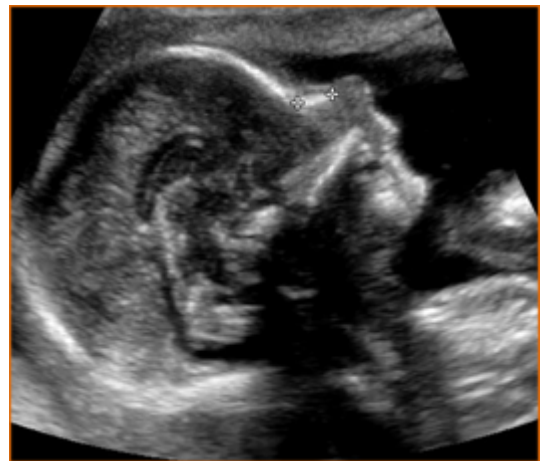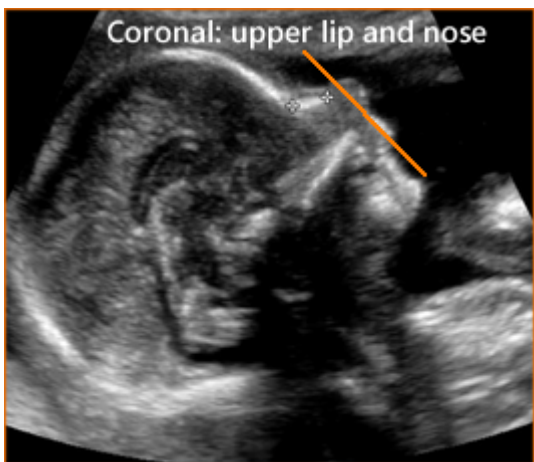


Above. Planes of view for cleft lip and cleft palate.

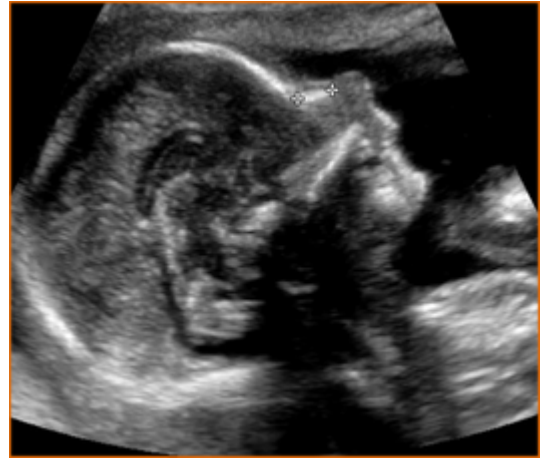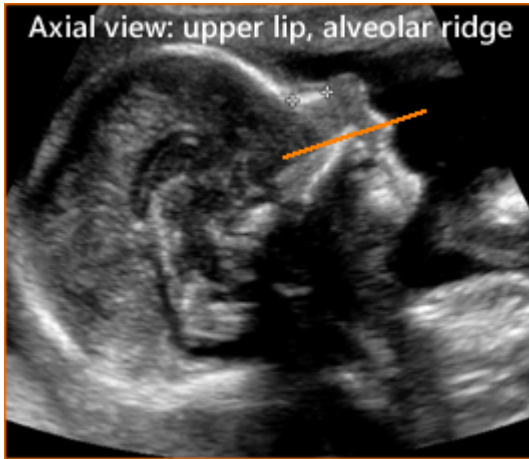To improve the detection rate of fetal clefts, the face should be viewed in 3 orthogonal planes (coronal, axial, and sagittal). The detection rate can be increased from about 20% to 30% when one or two planes are used, compared to 90% when all three planes are used. [\[10\]](#)



Above. Mid-sagittal, 2-D ultrasound view of the fetal head with nasal bone, nose, and lips outlined.

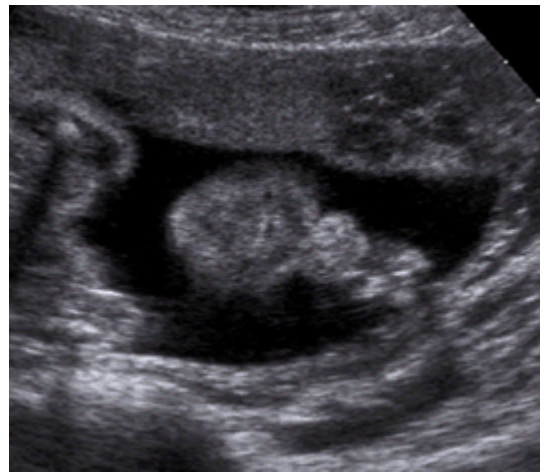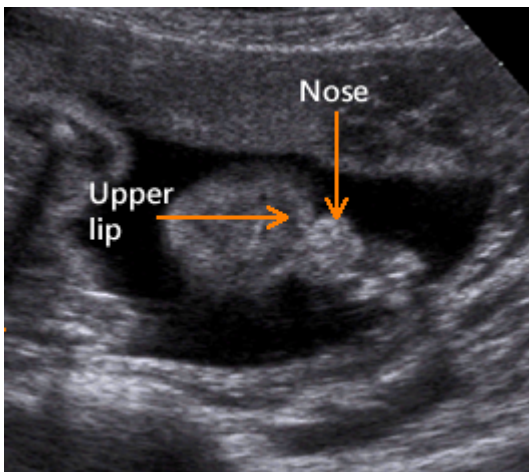


Above. The oblique coronal view demonstrates the visualization plane for the upper lip and nose.

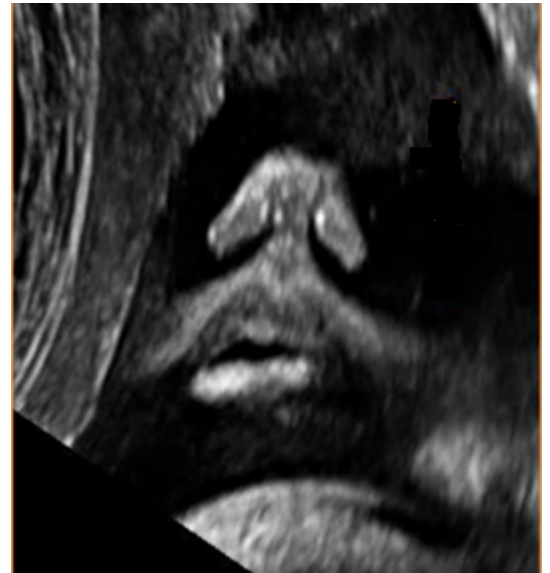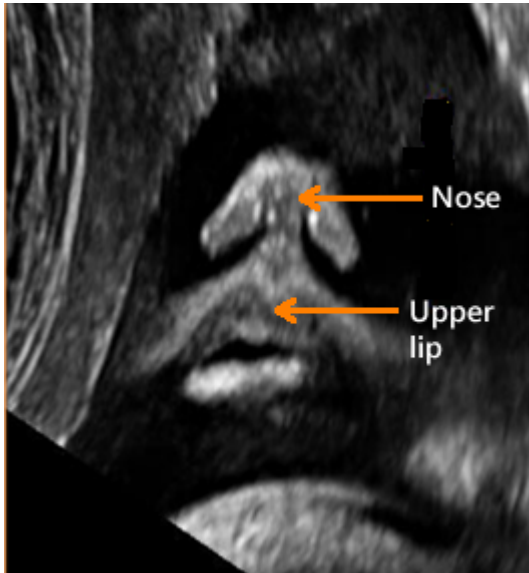


Above. The approximate axial or transverse view of the fetal maxilla and upper lip allows visualization of the lip, alveolar ridge, tooth buds, and part of the hard palate.

Routine visualization of the fetal face and lip should be a part of the mid-trimester scan. Coronal views of the lips, tangential views of the maxillary alveolus, and a profile view of the face should be part of the examination. [\[11\]](#),[\[12\]](#)

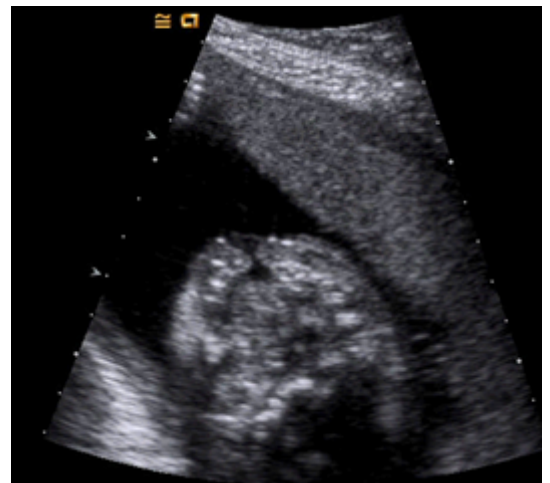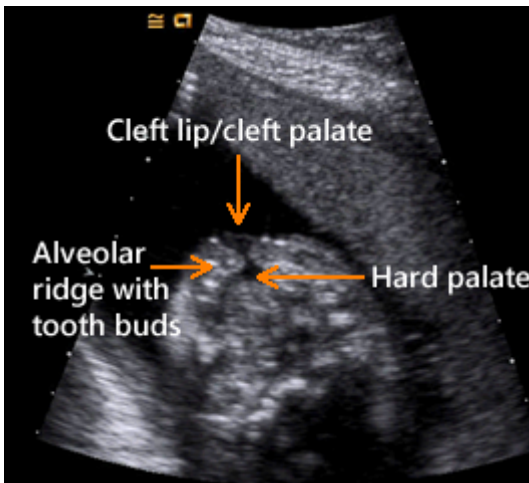


Above. Normal oblique coronal view of the fetal upper lip and nose.



Above. Normal oblique coronal view of the fetal upper lip and nose.

In a 2-D examination, images are obtained in the anterior coronal plane and the probe is moved from the nose and the mouth to the edge of the lips, thus obtaining the classic nose-mouth view.



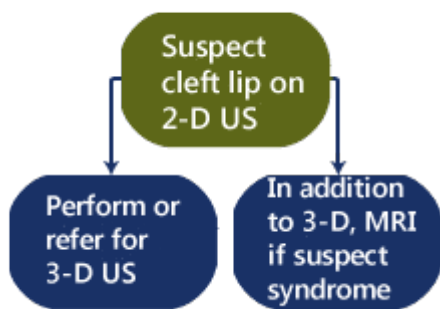
Above. Axial view of cleft lip and cleft palate demonstrating the alveolar ridge with tooth buds and the hard palate.

Serial axial/transverse views allow visualization of the nose down through the mouth to the lower edge of the mandible, thereby allowing assessment of the upper

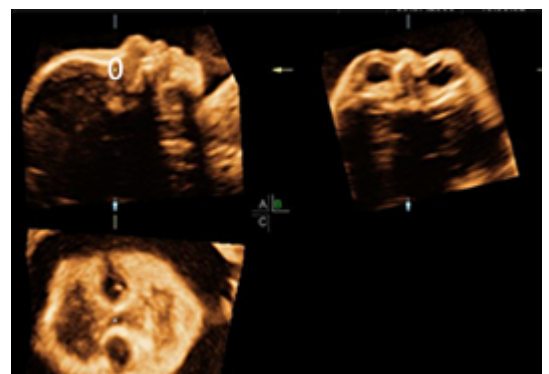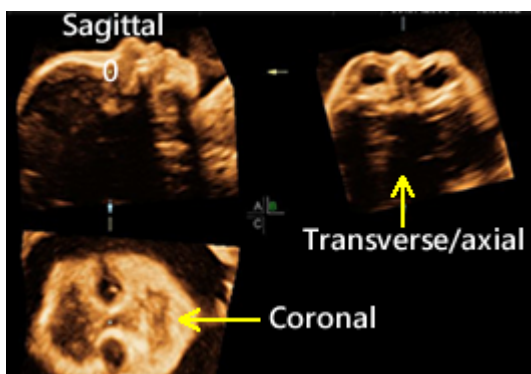
alveolar ridge, palate, tongue, and mandible. [13] Transvaginal ultrasound may be useful prior to 20 weeks.

With training and experience, the detection rate for facial clefts can be improved. [14] A new 2-D marker for the diagnosis of isolated cleft palate is termed the “equal sign” when a transverse plane images the uvula and soft palate, while a mid-sagittal plane assesses the soft palate and uvula. [15]

### 3-D Ultrasound



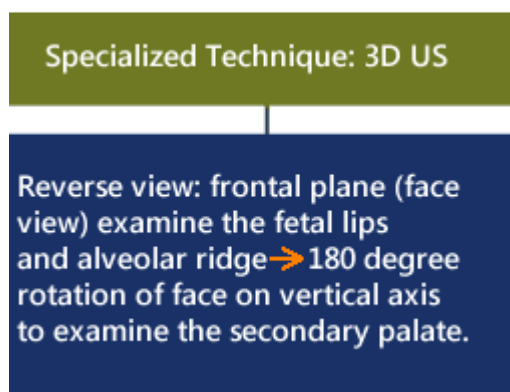
Current strategies suggest that 2-D ultrasound should be employed for screening, and when a cleft lip and/or palate is suspected, 3-D ultrasound should be the next step.



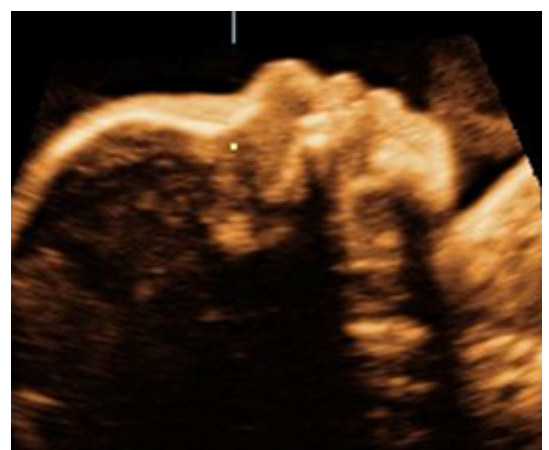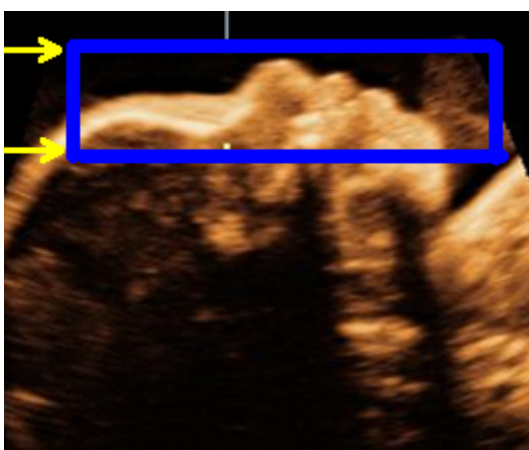
Above. Note the 3 reference planes for a 3-D sample volume.

As noted previously, increased detection is possible with 3-D which includes the

usual surface rendering and the orthogonal display permitting visualization in the three reference planes: sagittal, transverse, and coronal. The transverse plane can identify the alveolus and palate by visualizing the front tooth buds and alveolar ridge. When the volume is slightly rotated, the symmetry of the palate can be seen. [16] The surface rendering is useful in visually defining the defect.



Several techniques for 3-D ultrasound have been described and include the reverse view technique. [17] In the reverse view technique, the frontal plane is used to examine the fetal lips and alveolar ridge followed by a 180 degree rotation of the face on the vertical axis to examine the secondary palate.



Above. The planes in the reverse view technique are shown. The yellow arrow represents the frontal plane that is used to examine the fetal lips and alveolar ridge; while a 180 degree rotation of the face allows a view posterior to the face, which provides a view of the secondary plate and soft palate.

## Specialized Techniques: 3D US

Flipped face view: 3-D static volume acquired → rotated 90 degrees; cut plane is mid-sagittal then scrolled from chin to nose to include hard and soft palate

Oblique face view: secondary palate insonated at 45 degree angle in sagittal plane; 3-D US reconstructed in axial and coronal planes

In the flipped face view [\[18\]](#), a 3-D static volume is acquired, which is rotated 90 degrees so the cut plane is mid-sagittal from the chin to the nose. Scrolling from the chin to the nose allows sequential visualization of the lower lip, mandible, alveolar ridge, tongue, upper lip, maxilla, and alveolar ridge as well as the hard and soft palate.

In the oblique face view [\[19\]](#), the secondary palate is insonated at a 45 degree angle in the sagittal plane and 3-D ultrasound is reconstructed in the axial and coronal planes.

All three methods will visualize the upper lip and alveolar ridge [\[20\]](#), but with only 7 patients in a comparison study, it is difficult to render further judgment. A number of other 3-D ultrasound techniques are described, but none of those studies report detection of isolated cleft palate. [\[21\]](#)

## Facial Clefts MRI

## MRI

Supportive for diagnosis

Defines extent of bony defects

Detects other facial bony anomalies

Value at 20 weeks not fully known

MRI may play a useful role in the evaluation of facial clefts following 2-D ultrasound screening. MRI confirmed the diagnosis of CLP in 16 of 25 fetuses in whom the diagnosis was made by 2-D ultrasound [22], but MRI's greatest value was to define the extent of the cleft and to improve the morphologic study of the fetal facial bony anatomy. In another study conducted between 24 and 37 weeks, the positive predictive value of MRI for involvement of the palate was 96% and the negative predictive value was 80%. [23] MRI defines the primary and secondary plate and correlates well with postnatal or postmortem findings. [24] However, most of the studies have been conducted between 24 and 37 weeks and few reports demonstrate fetal examination at or below 20 weeks.

## Facial Clefts: Summary

### Summary

1. Development is multifactorial
2. Cleft lip: 25%, cleft palate: 25%  
cleft lip with palate 50%
3. Incidence: 1 in 500 to 1 in 1000  
live births.
4. 57% of the facial clefts isolated
5. Antenatal 2-D detection varies
6. 3-D ultrasound in a tertiary care  
improves detection (60 to 100%)

### Summary (continued)

7. If facial clefts are suspected on  
2-D, refer or perform 3-D US
8. MRI at 24 to 37 weeks supports  
diagnosis and defines extent of  
defects

1. The development of facial clefts is multifactorial.
2. Cleft lip accounts for 25%, cleft palate accounts for 25%, and cleft lip with palate accounts for 50%.
3. The incidence is about 1 in 500 to 1 in 1000 live births.
4. About 57% of the facial clefts are isolated and the remainder are associated with chromosomal aberrations (10%), syndromes or sequences (12%), and structural malformations only (21%).
5. The antenatal 2-D ultrasound detection rate varies widely (9 to 100%) and cleft palate is rarely detected.
6. 3-D ultrasound in a tertiary care setting improves detection (60 to 100%).
7. If facial clefts are suspected on 2-D ultrasound, 3-D should ideally be performed.

8. 3-D includes the usual surface rendering and the orthogonal display permitting visualization in the three reference planes: sagittal, transverse, and coronal.
9. A number of specialized techniques for 3-D ultrasound have been reported.
10. MRI at 24 to 37 weeks supports the diagnosis of facial cleft and is better able to define the extent of the defects compared to ultrasound.

## References

[Abstract: PMID: 11464997](#)

•

[\[back\]](#)

[Abstract: PMID: 4950925](#)

•

[\[back\]](#)

[Abstract: PMID: 3422598](#)

•

[\[back\]](#)

[Abstract: PMID: 11844160](#)

•

[\[back\]](#)

[Abstract: PMID: 18381773](#)

•

[\[back\]](#)

[Abstract: PMID: 17286264](#)

•

[\[back\]](#)

[Abstract: PMID: 11113886](#)

•

[\[back\]](#)

[Abstract: PMID: 19441124](#)

•

[\[back\]](#)

[Abstract: PMID: 20235140](#)

•

[\[back\]](#)

[Abstract: PMID: 8816530](#)

•

[\[back\]](#)

[Abstract: PMID: 11844160](#)

•

[\[back\]](#)

[Abstract: PMID: 24191520](#)

•

[\[back\]](#)

[Abstract: PMID: 22477739](#)

•

[\[back\]](#)

[Abstract: PMID: 18381773](#)

•

[\[back\]](#)

[Abstract: PMID: 20521240](#)

•

[\[back\]](#)

[Abstract: PMID: 22477739](#)

•

[\[back\]](#)

[Abstract: PMID: 15619313](#)

•

[\[back\]](#)

[Abstract: PMID: 17060428](#)

•

[\[back\]](#)

[Abstract: PMID: 17111460](#)

•

[\[back\]](#)

[Abstract: PMID: 19109803](#)

•

[\[back\]](#)

[Abstract: PMID: 22477739](#)

•

[\[back\]](#)

[Abstract: PMID: 21509548](#)

•

[\[back\]](#)

[Abstract: PMID: 20509765](#)

•

[\[back\]](#)

[Abstract: PMID: 20617504](#)

•

[\[back\]](#)